

Gray Matter Alterations in Obsessive–Compulsive Disorder: An Anatomic Likelihood Estimation Meta-Analysis

Jean-Yves Rotge^{*,1,2}, Nicolas Langbour¹, Dominique Guehl^{1,3}, Bernard Bioulac^{1,3}, Nematollah Jaafari⁴, Michele Allard^{5,6,7}, Bruno Aouizerate² and Pierre Burbaud^{1,3}

¹Laboratoire Mouvement Adaptation Cognition, CNRS UMR 5227, Université Bordeaux 2, Bordeaux, France; ²Service Universitaire de Psychiatrie, Centre Hospitalier Charles Perrens, Bordeaux, France; ³Service de Neurophysiologie Clinique, Centre Hospitalier Universitaire Pellegrin, Bordeaux, France; ⁴CIC-P U 802, Service Hospitalo-Universitaire de Psychiatrie Adulte, Centre Hospitalier Henri Laborit, Centre Hospitalier La Millétrie, Université de Poitiers, Poitiers, France; ⁵Laboratoire d'Imagerie Moléculaire et Fonctionnelle, CNRS UMR 5231, Université Bordeaux 2, Bordeaux, France; ⁶Service de Médecine Nucléaire, Centre Hospitalier Universitaire Pellegrin, Bordeaux, France; ⁷Ecole Pratique des Hautes Etudes, Bordeaux, France

Many voxel-based morphometry (VBM) studies have found abnormalities in gray matter density (GMD) in obsessive–compulsive disorder (OCD). Here, we performed a quantitative meta-analysis of VBM studies contrasting OCD patients with healthy controls (HC). A literature search identified 10 articles that included 343 OCD patients and 318 HC. Anatomic likelihood estimation meta-analyses were performed to assess GMD changes in OCD patients relative to HC. GMD was smaller in parieto-frontal cortical regions, including the supramarginal gyrus, the dorsolateral prefrontal cortex, and the orbitofrontal cortex, and greater in the basal ganglia (putamen) and the anterior prefrontal cortex in OCD patients relative to HC. No significant differences were found between children and adults. Our findings indicate differences in GMD in parieto-frontal areas and the basal ganglia between OCD patients and HC. We conclude that structural abnormalities within the prefrontal-basal ganglia network are involved in OCD pathophysiology.

Neuropsychopharmacology (2010) **35**, 686–691; doi:10.1038/npp.2009.175; published online 4 November 2009

Keywords: basal ganglia; meta-analysis; obsessive–compulsive disorder; parietal cortex; prefrontal cortex; voxel-based morphometry

INTRODUCTION

Obsessive–compulsive disorder (OCD) is a disabling anxiety disorder characterized by a chronic course. Over recent decades, several neuroimaging studies have contributed to identify changes in the brain that may mediate the disorder. For instance, functional abnormalities have been consistently described within frontosubcortical loops, which originate in the orbitofrontal cortex (OFC) (Menzies *et al*, 2008a).

A recently developed whole-brain technique, called voxel-based morphometry (VBM), allows voxel-wise between group comparisons of the local concentration of gray matter, often referred to as 'gray matter density' (GMD) (Ashburner and Friston, 2000). VBM allows researchers to locate structural abnormalities with high anatomic resolution, which contributes to the better understanding of OCD pathophysiology. However, results from VBM studies have remained inconsistent and controversial. For example, some studies have found that OCD patients have greater

OFC compared with control subjects (Valente *et al*, 2005; Szeszko *et al*, 2008; Yoo *et al*, 2008), and some other studies reported a smaller OFC in OCD patients (Pujol *et al*, 2004; Christian *et al*, 2008; Lázaro *et al*, 2009). Thus, a quantitative overview of VBM findings in OCD is necessary.

Here, we conducted an anatomic likelihood estimation (ALE) meta-analysis of VBM studies contrasting OCD patients and healthy controls (HC). The ALE method is a powerful voxel-based meta-analytic technique, which was originally designed for not only functional neuroimaging studies (Turkeltaub *et al*, 2002), but it is also appropriate for VBM studies (Ellison-Wright *et al*, 2008; Glahn *et al*, 2008). The aim of the present meta-analysis was to identify brain areas implicated across published VBM studies in OCD. Furthermore, to assess neurodevelopmental GMD changes in OCD, we compared structural abnormalities between children and adults.

MATERIALS AND METHODS

Literature Search and Study Selection

We searched the MEDLINE and PsycINFO databases through April 2009, without limits on the year of publication, using the keywords 'obsessive compulsive disorder,' 'imaging,' 'neuroimaging,' 'structural imaging,' 'magnetic

*Correspondence: Dr J-Y Rotge, Laboratoire Mouvement Adaptation Cognition, CNRS UMR 5227, Université Bordeaux 2, 146 rue Léo-Saignat, Bordeaux, Aquitaine 33076, France, Tel: +33 05 57 57 15 51, Fax: +33 05 56 90 14 21, E-mail: jeanyves.rotge@mac.com
Received 19 August 2009; revised 28 September 2009; accepted 29 September 2009

resonance imaging,' 'MRI,' 'morphometry,' or 'voxel-based morphometry.' The reference lists of identified articles and review articles were also searched to obtain additional papers. Studies were considered for inclusion if (1) they were published in English in a peer-reviewed journal, (2) they included subjects with a primary diagnosis of OCD on the basis of DSM-III, DSM-III-R, DSM-IV, or DSM-IV-R criteria, (3) they used the VBM method (Ashburner and Friston, 2000), (4) they compared an OCD group with an HC group, and (5) they reported whole-brain results and stereotactic (x , y , z) coordinates of group differences. To ensure that data were not entered twice from a study population that had been analyzed in more than one publication, all articles written by a given research group were carefully scrutinized. In such cases, we systematically included data from the authors' largest study population and excluded others. In case in which we could not determine data originality, we contacted the corresponding author to determine whether there was subject overlap between multiple studies.

We identified 10 VBM studies in our database search. These studies included 343 OCD patients (80 children and 263 adults) and 318 HC (69 children and 249 adults) (Pujol *et al*, 2004; Valente *et al*, 2005; Carmona *et al*, 2007; Christian *et al*, 2008; Szeszko *et al*, 2008; Gilbert *et al*, 2008a,b; Yoo *et al*, 2008; Lázaro *et al*, 2009; Van den Heuvel *et al*, 2009). Study selection was performed by one author (J-YR) and independently verified by another (NL).

Data Extraction

The identified articles included 66 foci (26 in children and 40 in adults), among which 23 corresponded to a greater gray matter (10 in children and 13 in adults) and 43 corresponded to a smaller gray matter (16 in children and 27 in adults) in OCD patients compared with HC. For each study, we identified the standardized atlas (Montreal Neurological Institute or Talairach spaces) and Standardized Precipitation Index (z -scores or t -values) that was used. The Montreal Neurological Institute coordinates were transformed into Talairach coordinates using the icbm2tal algorithm (Lancaster *et al*, 2007). For each focus, we extracted the corresponding coordinates, volumes, and SPI values. Data extraction was performed by one author (J-YR) and independently verified by another (NL).

ALE Meta-Analyses

ALE analyses were completed using Scribe, Sleuth, and GingerALE software (BrainMap, University of Texas) (Lancaster *et al*, 2007; Laird *et al*, 2005a,b). Separate ALE maps were created for coordinates associated with greater or smaller GMD in OCD patients compared with HC. Additional ALE maps were created for samples from children and adults, and they were then compared. Analyses were performed after recommendations from BrainMap (<http://www.brainmap.org>). A full-width half-maximum of 12 mm was used. A permutation test of randomly distributed foci allowed the determination of the statistical significance of the resulting ALE values, corrected for multiple comparisons. Five thousand permutations were performed using the same full-width half-maximum value

and the same number of foci used to compute ALE values. A conservative threshold for statistical significance was set at $p < 0.05$ (false discovery rate corrected) with a minimum cluster size of 400 mm³. We used MRICron software (<http://www.sph.sc.edu/comd/rorden/mricron/>) to visualize ALE maps overlaid onto a high-resolution brain template generated by the International Consortium for Brain Mapping (Kochunov *et al*, 2002).

RESULTS

The ten identified VBM studies and the main characteristics of the included populations are presented in Table 1. The results from ALE meta-analyses of VBM studies that included both children and adults are reported in Table 2 and depicted in Figure 1. GMD was smaller in many cortical areas, including the frontal eye fields (FEF) (Brodmann Area[BA] 8, superior frontal gyrus), supramarginal gyrus (BA 40), dorsolateral prefrontal cortex (DLPFC) (BA 9, middle frontal gyrus), and the medial part of the anterior prefrontal cortex (aPFC) (BA 10, medial frontal gyrus). GMD was greater in the putamen and in the lateral part of the OFC (BA 47, inferior frontal gyrus) in patients with OCD.

The results from ALE meta-analyses of children and adult samples are presented in Supplementary Materials (Supplementary Tables S1–2; Supplementary Figures S1–2). To assess differences in GMD with age, we compared the ALE maps generated for children and adult samples. No significant difference was found.

We next examined the effect of the statistical threshold chosen for the generation of ALE maps. The use of a more conservative threshold ($p < 0.01$) did not affect the results for any reported analysis, except that cluster volumes were generally smaller, requiring consideration of clusters under 400 mm³.

Finally, we conducted leave-one-out sensitivity analyses by repeating the analyses with the consecutive exclusion of each study to ensure that the overall results were not influenced by a single study. We found no marked differences regarding cerebral regions that showed GMD differences when using cluster size < 400 mm³. No significant differences were found when comparing each generated ALE map to the overall ALE map (Figure 1).

DISCUSSION

The present voxel-based meta-analysis pooled VBM studies that found structural changes in gray matter in 343 OCD patients. Our results showed that OCD patients exhibited smaller GMD in several parietal and frontal cortical areas and greater GMD in the basal ganglia and in the lateral part of the OFC. The findings from the present meta-analysis are consistent with currently accepted neurobiological models of OCD, which focus on dysfunction in OFC-striatal circuits. In a recent review, Menzies *et al* (2008a) showed that findings from anatomical and functional neuroimaging studies are compatible with those from cognitive studies. Furthermore, the authors outlined the involvement of areas other than the OFC and striatum in OCD, in particular the DLPFC and the parietal cortex.

Table 1 Included Voxel-Based Morphometry Studies

	Subjects	Number of subjects	Age mean (SD)	% of medicated patients	Y-BOCS score mean (SD)	Smaller GMD	Greater GMD
<i>Samples from children</i>							
Carmona <i>et al</i> (2007)	OCD	18	12.9 (2.8)	55.6	21.4 (5.9)		×
	HC	18	13 (3)	—	—		
Szeszko <i>et al</i> (2008)	OCD	37	13 (2.7)	0	24.9 (6.0)	×	×
	HC	26	13 (2.6)	—	—		
Gilbert <i>et al</i> (2008a)	OCD	10	12.9 (2.7)	0	26.5 (5.4)		×
	HC	10	13.4 (2.6)	—	—		
Lázaro <i>et al</i> (2009)	OCD	15	13.7 (2.5)	0	25.9 (5.6)		×
	HC	15	14.3 (2.5)	—	—		
<i>Samples from adults</i>							
Pujol <i>et al</i> (2004)	OCD	72	29.8 (10.5)	75	26.7 (7.1)	×	×
	HC	72	30.1 (10.2)	—	—		
Valente <i>et al</i> (2005)	OCD	19	32.7 (8.8)	57.9	24.6 (7.4)	×	×
	HC	15	32.3 (11.8)	—	—		
Gilbert <i>et al</i> (2008b)	OCD	25	37.5 (10.7)	80	26.9 (6.3)	×	×
	HC	20	29.8 (7.9)	—	—		
Yoo <i>et al</i> (2008)	OCD	71	26.6 (7.5)	83.1	22.8 (8.4)	×	×
	HC	71	26.7 (6.1)	—	—		
Christian <i>et al</i> (2008)	OCD	21	38 (9.6)	81	27.0 (5.2)	×	
	HC	21	38.9 (9.8)	—	—		
Van den Heuvel <i>et al</i> (2009)	OCD	55	33.7 (9.2)	0	22.8 (6.1)		×
	HC	50	31.4 (7.6)	—	—		

OCD, obsessive-compulsive disorder; HC, healthy controls; Y-BOCS, yale-brown obsessive-compulsive scale; GMD, gray matter density; SD, standard deviation.

Table 2 Gray Matter Density Changes in all OCD Patients Relative to Healthy Controls

Brain regions	Brodmann area	Talairach coordinates			Volume (mm ³)	Maximum ALE value (× 10 ³)
		x	y	z		
Gray matter density reduction						
R superior frontal gyrus	8	21	24	47	1152	6.4
L middle frontal gyrus	9	−35	26	36	960	5.2
R medial frontal gyrus	10	13	54	12	640	4.4
R middle frontal gyrus	9	41	33	30	536	4.0
R supramarginal gyrus	40	57	−44	33	424	4.1
Gray matter density enhancement						
L inferior frontal gyrus	47	−21	18	−14	1120	4.1
R putamen	—	19	15	−2	960	4.2
L putamen	—	−26	7	3	864	4.1

L, left; R, right; ALE, anatomic likelihood estimation.

Recently, a prior meta-analysis of ROI volume studies in OCD reported a smaller volume in the OFC, in the anterior cingulate cortex (ACC), and a higher volume in the thalamus, but no change in the basal ganglia (Rotge *et al*, 2009). The results from this ROI meta-analysis seem to be in contrast to the present findings from a VBM meta-analysis.

There may be many reasons for such discrepancies. First, there were a larger number of studies included in the ROI meta-analysis than in the VBM meta-analysis, which may minimize the risk of false negatives in ROI studies. Second, clinical samples from studies included in the ROI meta-analysis differ from those included in the VBM

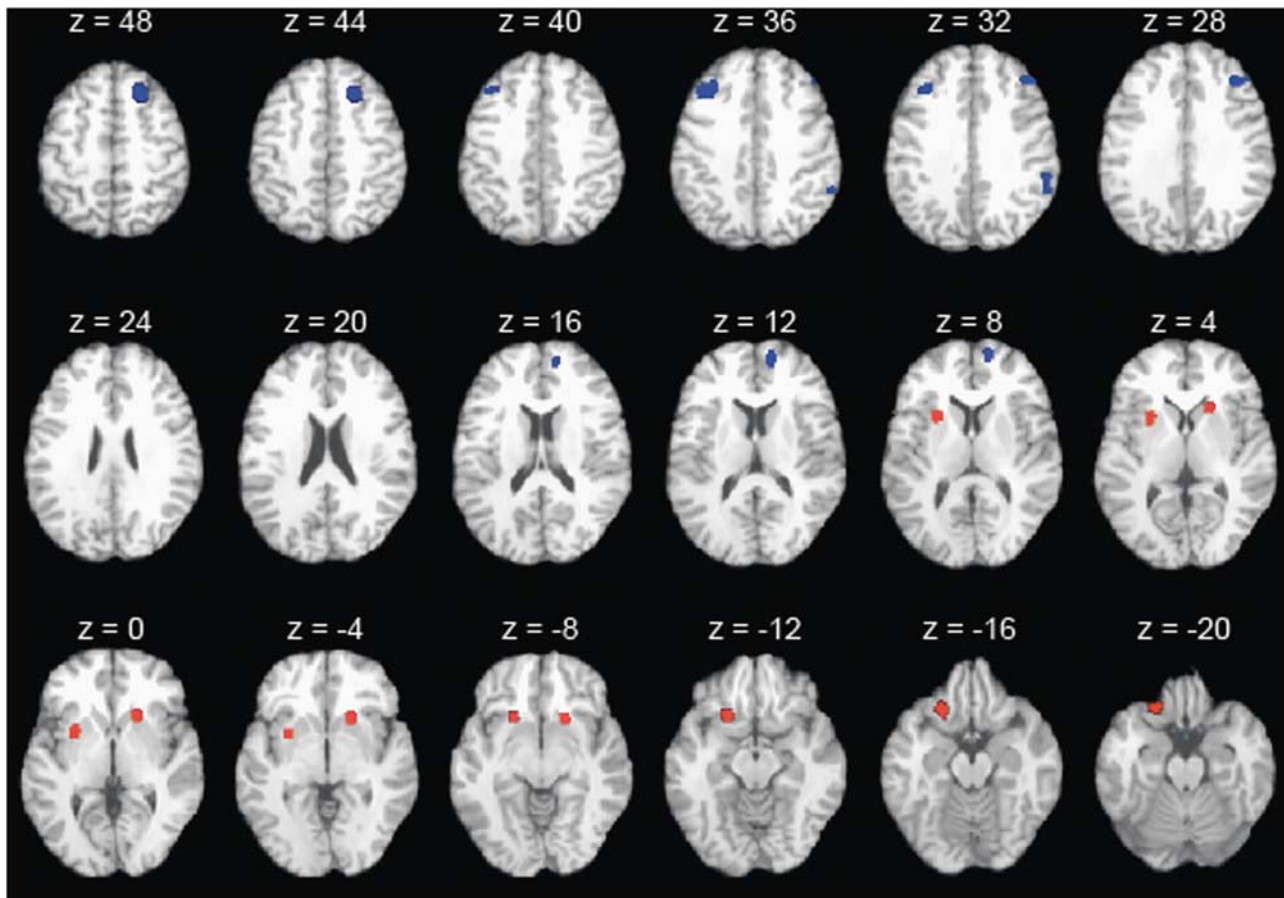


Figure 1 ALE map investigating differences in GMD between OCD patients and healthy subjects. Regions in blue are associated with a smaller gray matter in OCD patients relative to HC. Regions in red are associated with greater gray matter in OCD patients relative to HC. Smaller gray matter was found in the right superior frontal gyrus ($z = 48, 44$), left middle frontal gyrus ($z = 40, 36, 32$), right medial frontal gyrus ($z = 16, 12, 8$), right middle frontal gyrus ($z = 32, 28$), and the right supramarginal gyrus ($z = 36, 32$). Greater gray matter was found in the left inferior frontal gyrus ($z = -12, -16, -20$), right putamen ($z = 4, 0, -4, -8$), and the left putamen ($z = 8, 4, 0, -4, -8$).

meta-analysis. For example, the ROI meta-analysis mainly includes adult studies, whereas 40% of the studies of VBM meta-analysis corresponded to samples from children. Finally and most importantly, methodological differences between ROI and VBM techniques may account for these discrepancies. Indeed, VBM is useful for identifying brain abnormalities within whole brains, but factors other than volume alone may influence VBM results. For example, changes in the shape or displacement of structures in the course of spatial normalization may affect the final results (Kubicki *et al*, 2002). However, VBM studies and the present meta-analysis extend results from the prior ROI meta-analysis and provide new information regarding structural alterations in OCD. This is especially true for brain regions that have been poorly investigated in ROI studies, such as the parietal cortex or DLPFC, and for subterritories of a given brain region, such as the prefrontal cortex.

Smaller GMD was identified in the FEF, DLPFC, supramarginal gyrus, and aPFC. These structural changes may be related to neuropsychological impairments described in OCD patients. Spengler *et al* (2006) described oculomotor impairments and a higher frequency of anticipatory saccades in OCD patients relative to HC,

suggesting the existence of dysfunctional events in the FEF of OCD patients. Furthermore, there is evidence for dysfunction of the DLPFC in OCD. Impairments in executive functions, such as planning, have been described in OCD patients. These deficits were associated with decreased activation in this cortical area when compared with HC (Van den Heuvel *et al*, 2005). Smaller GMD found in the supramarginal gyrus, a part of the parietal cortex, is consistent with diffusion tensor imaging studies (Menzies *et al*, 2008b) that showed white matter abnormalities in this brain region and with functional imaging studies that showed a negative relationship between regional cerebral blood flow and symptom intensity (McGuire *et al*, 1994). These findings suggest that the supramarginal gyrus may have a function in the ability of patients to resist the obsessive processes. However, the functional contribution of this cortical area to OCD remains unclear and further studies are required to investigate its function in OCD pathophysiology. Finally, GMD was also found to be smaller within the aPFC. Many neuroimaging studies have shown that this cortical area is involved in multiple cognitive tasks. However, when examining commonalities across studies, Ramnani and Owen (2004) have proposed that the aPFC should contribute to the coordination of information

processing and information transfer between multiple operations across the supramodal cortex. In regard to OCD phenomenology, it could be assumed that dysfunction of the aPFC could play a role in deficits in cognitive flexibility, in particular in cognitive reallocation, which may contribute to maintenance of repetitive behaviors. However, the specific function of the aPFC in OCD remains unknown and awaits clarification.

Greater GMD was identified in the bilateral putamen, which is a part of the striatum. This finding is consistent with neurobiological models of OCD and with functional neuroimaging studies suggesting that dysfunction in the putamen contributes to the pathogenesis of OCD (Menzies *et al*, 2008a; Rauch *et al*, 1997). Furthermore, OCD symptom severity was associated with metabolic activity in the putamen (Kwon *et al*, 2003), whereas decreased metabolic activity in the putamen after pharmacological treatment was associated with an improvement in cognitive function in OCD patients (Kang *et al*, 2003). GMD was also found to be greater in the lateral part of the OFC in OCD patients compared with HC. The OFC is thought to have a function in several cognitive processes, such as the selection, comparison, and judgment of motivationally salient stimuli, and in the motivational aspects of decision making. In particular, the OFC has a function in error prediction by encoding the representation of the value of an expected outcome, which is used to anticipate the positive and negative consequences that are likely to follow a given action (O'Doherty, 2007; Wallis, 2007). The OFC also increases the evaluation of the occurrence of negative consequences that may follow an action in OCD and, therefore, mediates obsessive thoughts that lead to repetitive or ritualistic behaviors intended to prevent negative consequences as a way to relieve anxiety. The OFC is likely related to deficits of cognitive regulation of emotionally salient information. Accordingly, Chamberlain *et al* (2008) recently showed that, in comparison with HC, lateral OFC activation is reduced during a task that assesses behavioral flexibility in OCD patients and in unaffected relatives. These findings suggest that the lateral OFC could have a central function in cognitive flexibility deficits and, thus, in the genesis of pathological habits (Chamberlain *et al*, 2008).

In the present meta-analysis, we failed to show any significant differences in GMD between children and adults. This was an unexpected result because many factors should reasonably contribute to GMD changes with aging. First, children and adults differ for different clinical variables, such as illness duration, age of onset, or treatment intervention, which may potentially influence neuroimaging findings. Second, there are several lines of evidence in the literature suggesting that OCD is a neurodevelopmental disorder. Rosenberg and Keshavan (1998) proposed that OCD may be underlined by 'a developmentally mediated network dysplasia in prefrontal cortical circuits'. This neurodevelopmental view may be supported by differences in GMD between children and adults. One possible explanation for the absence of any significant differences between pediatric and adult samples may be the low number of foci, which may contribute to false negative results. Further hypothesis-driven ROI studies could be helpful to resolve this issue.

The present meta-analysis has several limitations. First, our meta-analysis is subject to publication bias. Studies that failed to show significant effects may not have been published. In the present meta-analysis, we identified only 10 VBM studies and we did not identify any articles without an effect. Second, we failed to consider clinical variables, such as symptom dimensions, medication status, comorbidity status, and symptom severity scores. Although these variables may be associated with differential structural abnormalities, the low number of VBM studies did not allow us to control for these factors. However, the absence of marked difference when consecutively excluding each study argues in favor of the robustness of our findings despite the clinical heterogeneity of study populations.

In conclusion, the present meta-analysis of VBM studies showed that OCD patients exhibited gray matter abnormalities in parieto-frontal cortical areas and in the basal ganglia. Further structural neuroimaging studies are required to assess gray matter changes associated with clinical correlates. Furthermore, functional studies may be helpful to elucidate the specific function of these areas in the genesis of OCD symptoms.

ACKNOWLEDGEMENTS

J-Y Rotge was supported by a grant from the Fondation pour la Recherche Médicale (Medical Research Foundation).

DISCLOSURE

The authors declare no conflict of interest.

REFERENCES

- Ashburner J, Friston KJ (2000). Voxel-based morphometry—the methods. *NeuroImage* 11: 805–821.
- Carmona S, Bassas N, Rovira M, Gispert JD, Soliva JC, Prado M *et al* (2007). Pediatric OCD structural brain deficits in conflict monitoring circuits: a voxel-based morphometry study. *Neurosci Lett* 421: 218–223.
- Chamberlain SR, Menzies L, Hampshire A, Suckling J, Fineberg NA, del Campo N *et al* (2008). Orbitofrontal dysfunction in patients with obsessive-compulsive disorder and their unaffected relatives. *Science* 321: 421–422.
- Christian CJ, Lencz T, Robinson DG, Burdick KE, Ashtari M, Malhotra AK *et al* (2008). Gray matter structural alterations in obsessive-compulsive disorder: relationship to neuropsychological functions. *Psychiatry Res* 164: 123–131.
- Ellison-Wright I, Glahn DC, Laird AR, Thelen SM, Bullmore ET (2008). The anatomy of first-episode and chronic schizophrenia: an anatomical likelihood estimation meta-analysis. *Am J Psychiatry* 165: 1015–1023.
- Gilbert AR, Keshavan MS, Diwadkar V, Nutche J, Macmaster F, Easter PC *et al* (2008a). Gray matter differences between pediatric obsessive-compulsive disorder patients and high-risk siblings: a preliminary voxel-based morphometry study. *Neurosci Lett* 435: 45–50.
- Gilbert AR, Mataix-Cols D, Almeida JR, Lawrence N, Nutche J, Diwadkar V *et al* (2008b). Brain structure and symptom dimension relationships in obsessive-compulsive disorder: a voxel-based morphometry study. *J Affect Disord* 109: 117–126.
- Glahn DC, Laird AR, Ellison-Wright I, Thelen SM, Robinson JL, Lancaster JL *et al* (2008). Meta-analysis of gray matter anomalies

- in schizophrenia: application of anatomic likelihood estimation and network analysis. *Biol Psychiatry* **64**: 774–781.
- Kang DH, Kwon JS, Kim JJ, Youn T, Park HJ, Kim MS *et al* (2003). Brain glucose metabolic changes associated with neuropsychological improvements after 4 months of treatment in patients with obsessive-compulsive disorder. *Acta Psychiatr Scand* **107**: 291–297.
- Kochunov P, Lancaster J, Thompson P, Toga AW, Brewer P, Hardies J *et al* (2002). An optimized individual target brain in the Talairach coordinate system. *NeuroImage* **17**: 922–927.
- Kubicki M, Shenton ME, Salisbury DF, Hirayasu Y, Kasai K, Kikinis R *et al* (2002). Voxel-based morphometric analysis of gray matter in first episode schizophrenia. *NeuroImage* **17**: 1711–1719.
- Kwon JS, Kim JJ, Lee DW, Lee JS, Lee DS, Kim MS *et al* (2003). Neural correlates of clinical symptoms and cognitive dysfunctions in obsessive-compulsive disorder. *Psychiatry Res* **122**: 37–47.
- Laird AR, Fox M, Price CJ, Glahn DC, Uecker AM, Lancaster JL *et al* (2005a). ALE meta-analysis: controlling the false discovery rate and performing statistical contrasts. *Hum Brain Mapp* **25**: 155–164.
- Laird AR, Lancaster JL, Fox PT (2005b). BrainMap: the social evolution of a functional neuroimaging database. *Neuroinformatics* **3**: 65–78.
- Lancaster JL, Tordesillas-Gutierrez D, Martinez M, Salinas F, Evans A, Zilles K *et al* (2007). Bias between MNI and Talairach coordinates analyzed using the ICBM-152 brain template. *Hum Brain Mapp* **28**: 1194–1205.
- Lázaro L, Bargalló N, Castro-Fornieles J, Falcón C, Andrés S, Calvo R *et al* (2009). Brain changes in children and adolescents with obsessive-compulsive disorder before and after treatment: a voxel-based morphometric MRI study. *Psychiatry Res* **172**: 140–146.
- McGuire PK, Bench CJ, Frith CD, Marks IM, Frackowiak RS, Dolan RJ (1994). Functional anatomy of obsessive-compulsive phenomena. *Br J Psychiatry* **164**: 459–468.
- Menzies L, Chamberlain SR, Laird AR, Thelen SM, Sahakian BJ, Bullmore ET (2008a). Integrating evidence from neuroimaging and neuropsychological studies of obsessive-compulsive disorder: the orbitofronto-striatal model revisited. *Neurosci Biobehav Rev* **32**: 525–549.
- Menzies L, Williams GB, Chamberlain SR, Ooi C, Fineberg N, Suckling J *et al* (2008b). White matter abnormalities in patients with obsessive-compulsive disorder and their first-degree relatives. *Am J Psychiatry* **165**: 1308–1315.
- O'Doherty JP (2007). Lights, camembert, action! The role of human orbitofrontal cortex in encoding stimuli, rewards, and choices. *Ann NY Acad Sci* **1121**: 254–272.
- Pujol J, Soriano-Mas C, Alonso P, Cardoner N, Menchón JM, Deus J *et al* (2004). Mapping structural brain alterations in obsessive-compulsive disorder. *Arch Gen Psychiatry* **61**: 720–730.
- Ramnani N, Owen AM (2004). Anterior prefrontal cortex: insights into function from anatomy and neuroimaging. *Nat Rev Neurosci* **5**: 184–194.
- Rauch SL, Savage CR, Alpert NM, Dougherty D, Kendrick A, Curran T *et al* (1997). Probing striatal function in obsessive-compulsive disorder: a PET study of implicit sequence learning. *J Neuropsychiatry Clin Neurosci* **9**: 568–573.
- Rosenberg DR, Keshavan MS (1998). Toward a neurodevelopmental model of obsessive-compulsive disorder. *Biol Psychiatry* **43**: 623–640.
- Rotge JY, Guehl D, Dilharreguy B, Tignol J, Bioulac B, Allard M *et al* (2009). Meta-analysis of brain volume changes in obsessive-compulsive disorder. *Biol Psychiatry* **65**: 75–83.
- Spengler D, Trillenberg P, Sprenger A, Nagel M, Kordon A, Junghanns K *et al* (2006). Evidence from increased anticipation of predictive saccades for a dysfunction of fronto-striatal circuits in obsessive-compulsive disorder. *Psychiatry Res* **143**: 77–88.
- Szeszko PR, Christian C, MacMaster F, Lencz T, Mirza Y, Taormina SP *et al* (2008). Gray matter structural alterations in psychotropic drug-naïve pediatric obsessive-compulsive disorder: an optimized voxel-based morphometry study. *Am J Psychiatry* **165**: 1299–1307.
- Turkeltaub PE, Eden GF, Jones KM, Zeffiro TA (2002). Meta-analysis of the functional neuroanatomy of single-word reading: method and validation. *NeuroImage* **16**: 765–780.
- Valente AA, Miguel EC, Castro CC, Amaro E, Duran FLS, Buchpiguel CA *et al* (2005). Regional gray matter abnormalities in obsessive-compulsive disorder: a voxel-based morphometry study. *Biol Psychiatry* **58**: 479–487.
- Van den Heuvel OA, Remijnse PL, Mataix-Cols D, Vrenken H, Groenewegen HJ, Uylings HB *et al* (2009). The major symptom dimensions of obsessive-compulsive disorder are mediated by partially distinct neural systems. *Brain* **132**: 853–868.
- Van den Heuvel OA, Veltman DJ, Groenewegen HJ, Cath DC, van Balkom AJ, van Hartskamp J *et al* (2005). Frontal-striatal dysfunction during planning in obsessive-compulsive disorder. *Arch Gen Psychiatry* **62**: 301–309.
- Wallis JD (2007). Orbitofrontal cortex and its contribution to decision-making. *Annu Rev Neurosci* **30**: 31–56.
- Yoo SY, Roh MS, Choi JS, Kang DH, Ha TH, Lee JM *et al* (2008). Voxel-based morphometry study of gray matter abnormalities in obsessive-compulsive disorder. *J Korean Med Sci* **23**: 24–30.

Supplementary Information accompanies the paper on the Neuropsychopharmacology website (<http://www.nature.com/npp>)